



EFFICACY OF DRY NEEDLING IN POST TOTAL KNEE REPLACEMENT SURGERY WITH ARTHROFIBROSIS- CASE REPORT

Ajeet Mandal¹, Nidhi Tiwari², Dr. S. Senthil Kumar³

¹ Mpt student, School of Health Sciences, Department of physiotherapy, Garden City University, Bengaluru, Karnataka, India

² Mpt Student, School of Health Sciences, Department of physiotherapy, Garden City University, Bengaluru, Karnataka, India

³ Research Supervisor and Professor, School of Health Sciences, Department of Physiotherapy, Garden City University, Bengaluru, Karnataka, India

Article DOI: <https://doi.org/10.36713/epra16868>

DOI No: 10.36713/epra16868

ABSTRACT

Background: TKR is a surgical technique where a synthetic or artificial joint replaces an inoperative knee joint. The main manifestations of TKR are discomfort and functional constraints. For individuals to be evaluated a candidate for TKR, their everyday activities tend to be significantly impacted by pain and functional limitations. An excessive immune reaction to a pro-inflammatory stimulus causes arthrofibrosis (AF), which is characterised by pathological periarticular fibrosis and ensuing symptoms including reduced joint range of motion. A rare, localised, and irreversible delayed impact of surgery that has been reported in a variety of tissues and organs is called postoperative fibrosis (POF). In this study we use dry needling as an approach towards arthrofibrosis which develop after total knee arthroplasty.

Case presentation: We presented the case of 69 year old female patient who had total knee arthroplasty and has fibrosis. Physiotherapy procedure was commenced along with dry needling.

Conclusion: As a result the physiotherapy with dry needling aided patient in his recovery.

KEY WORDS: Total Knee Replacement, Arthrofibrosis, Dry Needling, Physical Therapy, Case Report

INTRODUCTION

TKR is a surgical method where a damaged knee joint gets substituted with a prosthetic or artificial joint. Pain is the main indication of TKR, followed by functional impairment⁽¹⁾. Usually, a person's everyday activities must be considerably affected by pain and functional restrictions for him or her to be deemed a candidate for TKR. (TKR) By 2040, 78.4 million persons are expected to be affected by arthritis, with a lifetime prevalence of symptomatic knee arthritis anticipated at 44.7%⁽²⁾. Fast-track physical therapy-based total joint replacement programmes show promise in enhancing both the immediate and long-term rehabilitation following surgery. Patients enrolled in these fast-track programmes for total knee replacement (TKR) and total hip replacement (THR) exhibit higher levels of short-term functionality⁽³⁾. An excessive immune reaction to a pro-inflammatory stimulus causes arthrofibrosis (AF), which is characterised by pathological periarticular fibrosis and ensuing symptoms including reduced joint range of motion. The hallmark of AF is capsular constriction due to abnormal extracellular matrix deposition, which can result from hemarthrosis, postinfectious arthritis, surgical insult, or periarticular trauma. Primary AF seldom

happens, but when it does, it usually has an unknown cause⁽⁴⁾. People of various ages are affected by arthrofibrosis, with differing reported rates. Due to a lack of diagnostic biomarkers and a limited understanding of the pathophysiology, the risk factors and optimal therapy techniques remain mainly unclear⁽⁵⁾.

CASE PRESENTATION

A 69 year old female who is house wife complains of bilateral knee pain (L>R) which is insidious in onset and gradually progressive with symptoms like swelling, crepitus and medial joint line tenderness. Because of the pain her daily activity was hampered. She visited to hospital and was diagnosed with grade IV osteoarthritis of knee, due to which she undergone into a total knee replacement surgery, pre and post X-ray is shown in Fig1. Secondary to surgery she develops arthrofibrosis. Due to development of arthrofibrosis there was swelling and grade 2 tenderness on lateral aspect of knee and stiffness. Her manual muscle testing (MMT) and range of motion (ROM) seemed restricted. Robotics approach was used for her surgery and the implant which is been used was stryker. Since it was a comfortable position, she was laid out supine on the bed.

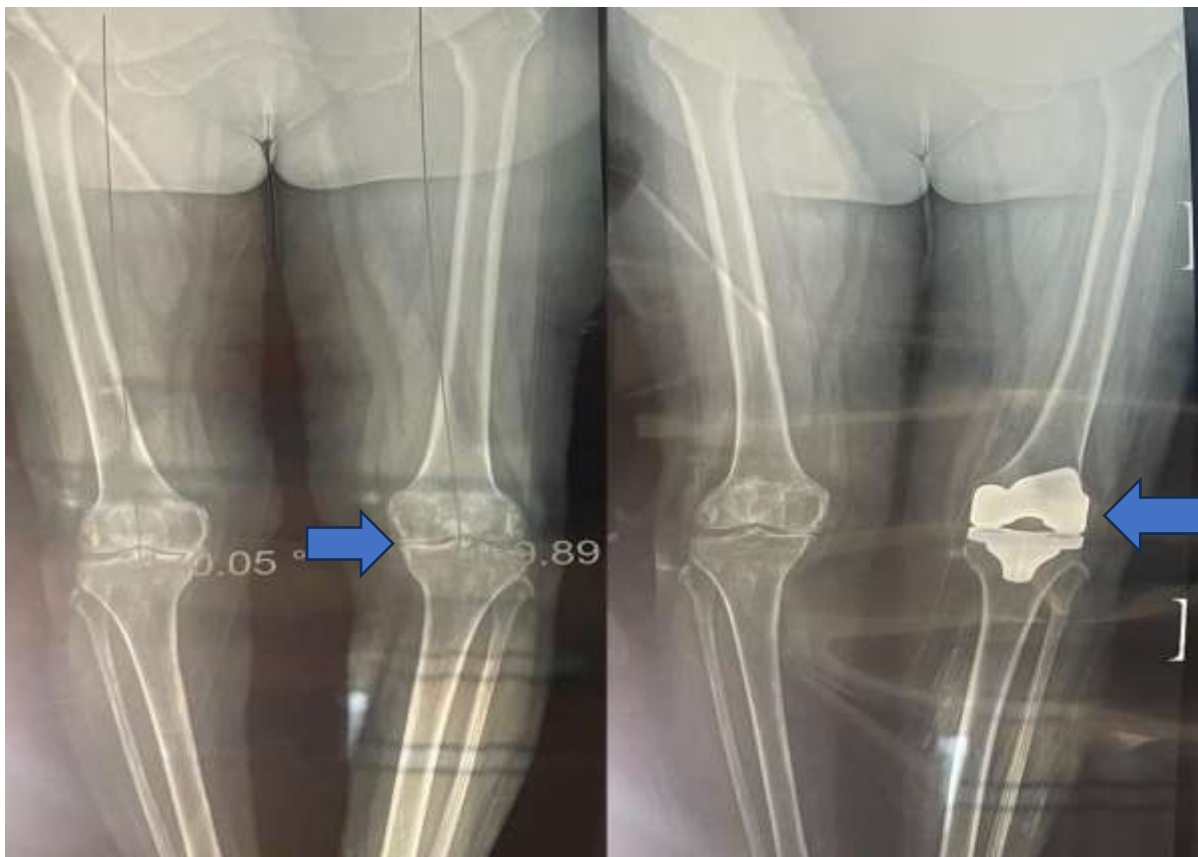


FIGURE 1: Pre and Post X-ray

PHYSIOTHERAPY INTERVENTION

Physical therapy was administered to the patient with the aim of boosting and recuperating the strength of their hip and knee

motions, as well as restoring the range of motion in those joints(6).

PHASE 1 (Day 0- Hospital discharge)	PHASE 2 (Hospital discharge – 6 weeks)	PHASE 3 (6 weeks- 12 weeks)	PHASE 4 (12 weeks & beyond)
Full Active movements to ankle and gentle movements of hip and knee. Passive heel slides and ATMs.	All phase 1 exercises, with modification for e.g. – heel slides with towel.	Continuing joint mobilization, quads table with resisted exercises.	Full range of motion exercises to ankle, hip and knee, stretching of quads, hamstrings and calf muscles.
Isometric exercises to quadriceps, gluteus and hamstrings muscles.	Prone knee flexion exercises, stationary bicycle and joint mobilizations.	Increase resistance using weight cuff for strengthening exercises.	Continue walking and bicycling. Dry needling for 10mins, 2 times a week.
Gentle hip abduction and adduction and SLR.	Stretching of hamstrings and gastrosoleus muscles, SLR is done without lag resistance exercises.	Eccentric control of quadriceps with closed chain exercises.	Proprioceptive exercises : Continuing all phase 3 exercises , increasing difficulty as tolerated. Endurance programme for 30-45mins, 3 times a week
Bed mobility and transfer techniques is taught, use of CPM for 20-30 degree of knee flexion.	Hip abduction, adduction and extension against gravity. Closed chain exercises including terminal knee exercises.	Balance and agility exercises is initiated.	
Non-weight bearing with support of walker.	Full weight bearing with gait training.	full weight bearing while requiring a walker for support.	Full weight bearing without support.

During the phase 4 of the physiotherapy protocol the dry needling practice was use, needle was prick in the knee shown in fig 2. As patient develop arthrofibrosis the dry needling shows the immense effect on the condition. Many articles

suggested that dry needling was effective in post TKA, but in this study dry needling shows the satisfactory results towards arthrofibrosis which develop after TKA.

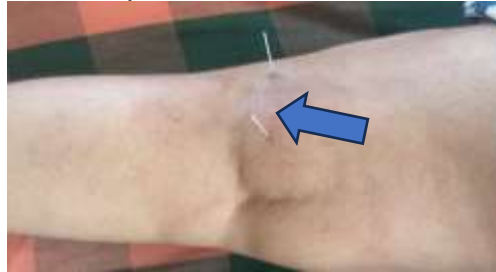

Figure 2: Dry Needling Practice

FOLLOW UP AND OUTCOME

Following appropriate rehabilitation, the individual's range of motion (ROM), both passive and active, had increased by the

time of discharge. Results from manual muscle testing (MMT) both before and after exhibited an improvement in muscle strength⁽⁶⁾.

JOINT		AROM		PROM	
HIP	BASELINE	DISCHARGE	BASELINE	DISCHARGE	
FLEXION	20 ⁰	110 ⁰	25 ⁰	115 ⁰	
EXTENSION	15 ⁰	25 ⁰	20 ⁰	30 ⁰	
ABDUCTION	30 ⁰	40 ⁰	35 ⁰	45 ⁰	
ADDUCTION	30 ⁰	40 ⁰	35 ⁰	45 ⁰	
KNEE					
FLEXION	20 ⁰	110 ⁰	25 ⁰	115 ⁰	

MUSCLE STRENGTH

PRE- TREATMENT	POST -TREATMENT
1	+3

DISCUSSION

One very incapacitating consequence of total knee arthroplasty (TKA) is arthrofibrosis. It is a standard cause of TKA failure and one of the main reasons for hospital readmission. Being conscious of this, physical therapy's objective in post TKA with arthrofibrosis is to restore the range of motion, muscle strength and reduce stiffness and pain. Dry needling combine with physical therapy shows the significant improvement in arthrofibrosis. More research and Subsequent randomised clinical trials ought to delve more into the efficacy of this strategy in comparable circumstances⁽⁷⁾.

The author Kate G Hendreson ,et.al in there systemic review and meta analysis shows the effectiveness of physiotherapy after TKA. The author in there study stated that physiotherapy regime shorten the hospital stay of patient and pain, activity and range of motion is also increased by physiotherapy and hydrotherapy respectively⁽⁸⁾.

Michelle R .Rauzi, et.al in there study author shows the effectiveness of physical therapy in arthrofibrosis after TKA, the author concluded that Seventy percent of patients refuse to be operated on while sedated, the implementation of the multimodal physical therapy programme is possible for treating early-stage arthrofibrosis following total knee arthroplasty. Physiotherapy helped patient gaining confident after arthrofibrosis after TKA⁽⁹⁾.

Rodrigo Nunez Cortes, et.al in there study author discussed about the effectiveness of dry needling combine with the

physical therapy. Author states that Patients with post-TKA chronic pain had statistically significant improvements in pain, function, range of motion, and myofascial trigger points following the use of dry needling in conjunction with therapeutic activities⁽¹⁰⁾.

CONCLUSION

Together, dry needling and physiotherapy sessions have significantly improved the patient's condition after TKA, but dry needling shows the significance effect in arthrofibrosis by reducing the symptoms. At the conclusion of the session, muscle strength, range of motion were increased , stiffness and pain was reduced after the session. The efficacy of this technique in comparable circumstances ought to be further explored in future randomised clinical trials.

REFERENCES

1. Total Knee Replacement. *Ont Health Technol Assess Ser.* 2005 Jun 1;5(9):1-51.
2. Nham FH, Patel I, Zalikha AK, El-Othmani MM. *Epidemiology of primary and revision total knee arthroplasty: analysis of demographics, comorbidities and outcomes from the national inpatient sample. Arthroplasty.* 2023 Apr 2;5(1):18.
3. Crespin DJ, Griffin KH, Johnson JR, Miller C, Finch MD, Rivard RL, et al. *Acupuncture Provides Short-term Pain Relief for Patients in a Total Joint Replacement Program. Pain Med Malden Mass.* 2015 Jun;16(6):1195-203.
4. Lee DR, Therrien E, Song BM, Camp CL, Krych AJ, Stuart MJ, et al. *Arthrofibrosis Nightmares - Prevention &*



- Management Strategies. *Sports Med Arthrosc Rev.* 2022 Mar 1;30(1):29–41.
5. Usher KM, Zhu S, Mavropalias G, Carrino JA, Zhao J, Xu J. Pathological mechanisms and therapeutic outlooks for arthrofibrosis. *Bone Res.* 2019 Mar 26;7:9.
 6. Tiwari N, Patil S, Popalbhat R, Tiwari N, Patil S, Popalbhat R. Efficacy of Physiotherapy Rehabilitation for Proximal Femur Fracture. *Cureus [Internet].* 2022 Oct 26 [cited 2024 Feb 22];14(10). Available from: <https://www.cureus.com/articles/120550-efficacy-of-physiotherapy-rehabilitation-for-proximal-femur-fracture>
 7. Cheuy VA, Foran JRH, Paxton RJ, Bade MJ, Zeni JA, Stevens-Lapsley JE. Arthrofibrosis Associated With Total Knee Arthroplasty. *J Arthroplasty.* 2017 Aug;32(8):2604–11.
 8. Henderson NC, Rieder F, Wynn TA. FIBROSIS: FROM MECHANISMS TO MEDICINES. *Nature.* 2020 Nov;587(7835):555–66.
 9. Rauzi MR, Foran JRH, Bade MJ. Multimodal conservative management of arthrofibrosis after total knee arthroplasty compared to manipulation under anesthesia: a feasibility study with retrospective cohort comparison. *Pilot Feasibility Stud.* 2022 Mar 25;8(1):71.
 10. Núñez-Cortés R, Cruz-Montecinos C, Vásquez-Rosel Á, Paredes-Molina O, Cuesta-Vargas A. Dry Needling Combined With Physical Therapy in Patients With Chronic Postsurgical Pain Following Total Knee Arthroplasty: A Case Series. *J Orthop Sports Phys Ther.* 2017 Mar;47(3):209–16.